

A promising material for improving therapeutic outcomes in patients

Hyaluronic acid in oral implantology

Dr Michael Claar, Kassel, Germany

Used on a routine basis in many areas of medicine, hyaluronic acid is now starting to be successfully employed in modern oral implantology as well. The following clinical case illustrates the use of hyaluronic acid in an external sinus floor elevation procedure with simultaneous insertion of two Bone Trust Plus implants (Medical Instinct).

Hyaluronic acid is a component of the extracellular matrix in virtually all types of tissues. In terms of chemistry, it is a naturally occurring polysaccharide belonging to the class of glycosaminoglycans (GSG). Many body cells are capable of producing hyaluronic acid in their cell membranes, thereby securing important metabolic transport pathways.

Besides these general properties of hyaluronic acid, it is also known that this substance is involved in various phases of wound healing. It promotes cellular proliferation, cell migration, and neoangiogenesis. The literature also documents the anti-bacterial and anti-inflammatory properties of hyaluronic acid.

Clinical case

A 28-year-old woman presented at our implant practice requesting insertion of a permanent implant at sites 14 and 15. The teeth had had to be removed at another clinic as a result of failed endodontic procedures (Figs. 1 and 17). Clinical and radiological examinations showed a lack of adequate vertical bone but an adequate width of the alveolar ridge. Given that the residual vertical bone height was 5 mm, we discussed augmentation with the patient in the form of a sinus floor elevation. Since 5 mm of residual bone is usually sufficient for adequate primary stability when using a modern implant system, we planned to insert the implants at the same time as the augmentation procedure.

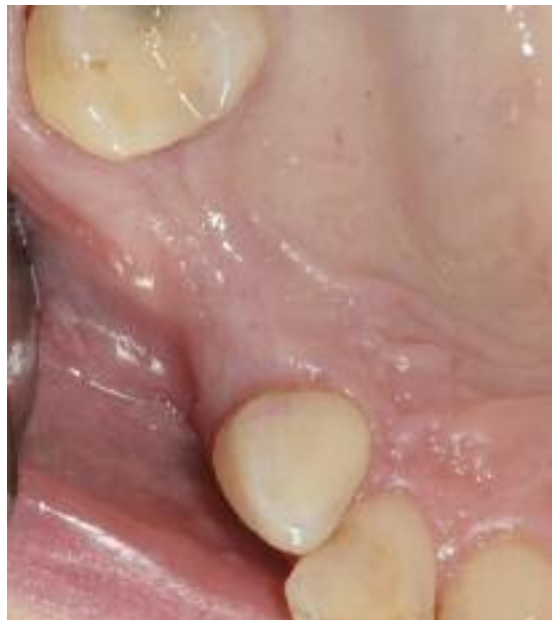The patient was informed about the option of the additional intraoperative application of hyaluronic acid to improve wound healing.

A trapezoid incision was made under local anaesthesia to reflect a mucoperiosteal flap (Fig. 2). The vestibular portion of the maxillary sinus was exposed

and a maxillary sinus cover was prepared with a diamond burr according to the classical protocol. This process revealed residue of a sealer located directly on the Schneiderian membrane (Fig. 3). Using blunt dissection, this was removed, taking care to preserve the integrity of the Schneiderian membrane to the maximum extent possible (Fig. 4).

We then performed the elevation. The implant cavities were mechanically prepared using a Medical Instinct drill set (Fig. 5). Here it is important to take care to avoid any accidental perforation of the mucosa of the maxillary sinus; it is clinically beneficial to protect the mucosa with a blunt instrument.

After complete preparation of the implant cavities, we continued by augmenting the sinus cavity with a bone regeneration material, which we had mixed



*Fig. 1
Clinical baseline
situation with
missing teeth
14 and 15.*

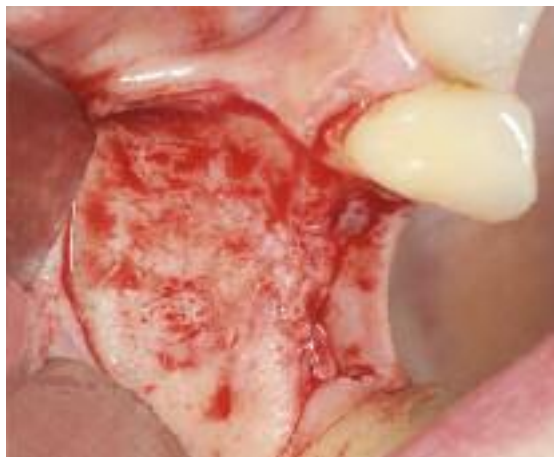

Fig. 2 Preparation of the mucoperiosteal flap to expose the vestibular wall of the maxillary sinus.

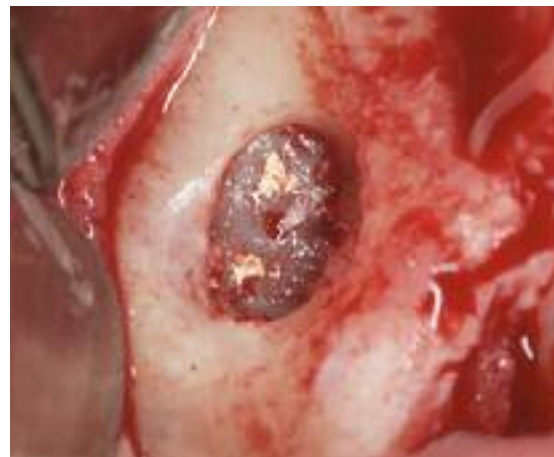

Fig. 3 Sealer residue on Schneiderian membrane.

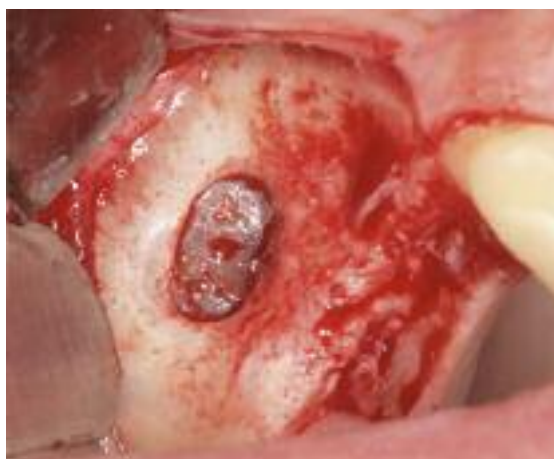

Fig. 4 The sealer residue has been removed without perforating the membrane.

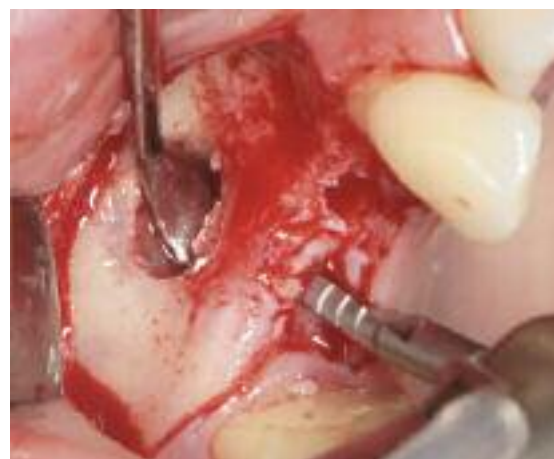

Fig. 5 Mechanical preparation of the implant cavities.

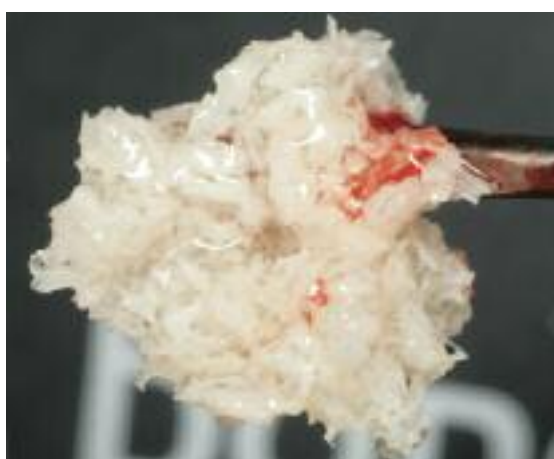

Fig. 6 Augmentation material with Tissue Support.

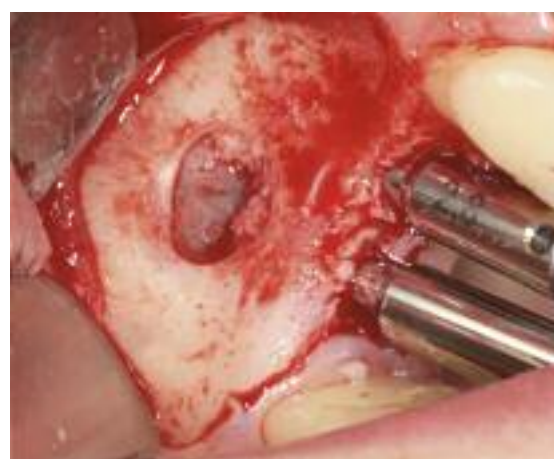

Fig. 7 Parallelization pins in situ.

with hyaluronic acid (Tissue Support) outside the mouth (Figs. 6 and 7). The great advantage of this technique is the plasticity or formability of the augmentation material resulting from the addition of

the Tissue Support hyaluronic acid Liqui Gels. This helps prevent displacement of the regeneration material and assures a high level of positional stability (Figs. 8 and 9).

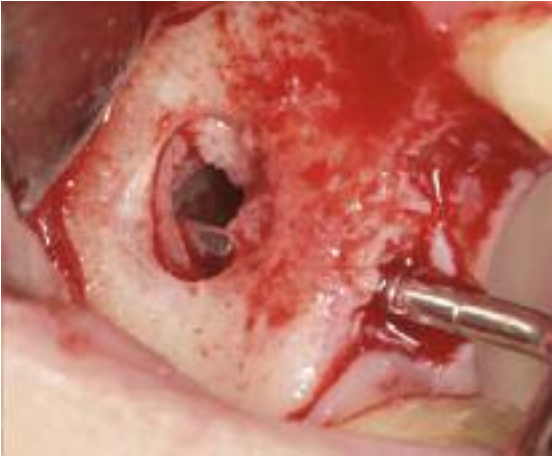

Fig. 8 Probing the implant cavity.

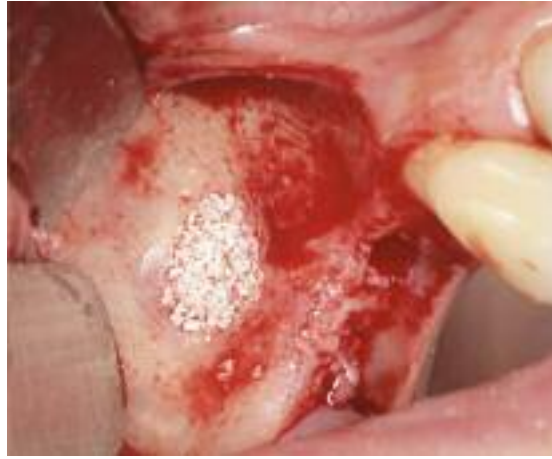

Fig. 9 Introducing the augmentation material.

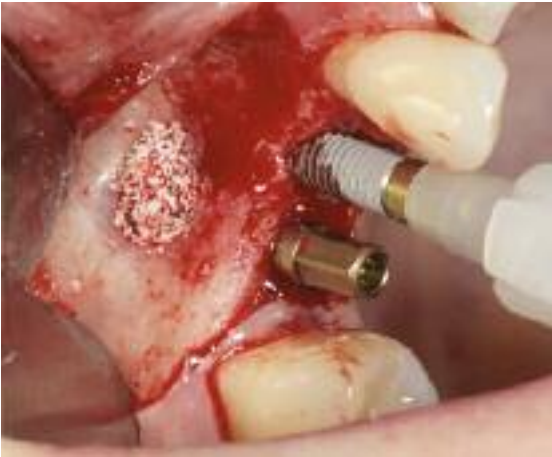

Fig. 10 Inserting the two Bone Trust Plus implants.

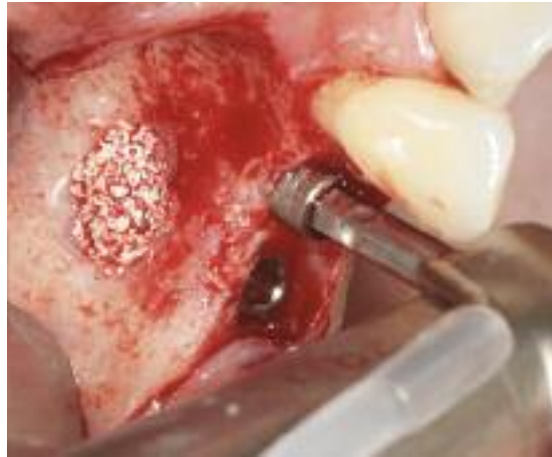

Fig. 11 Positioning the final implant.

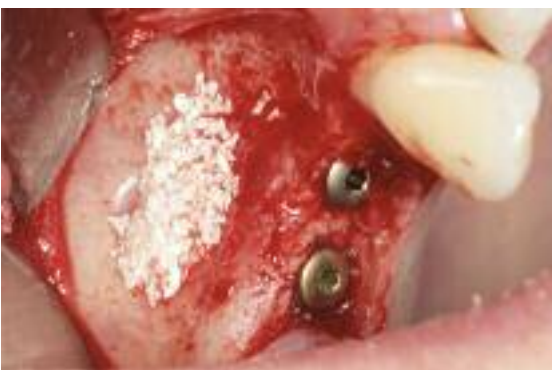

Fig. 12 Primary stability of the Bone Trust Plus implants.

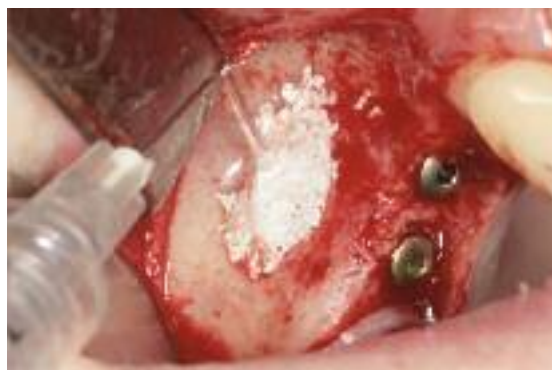

Fig. 13 Application of the Flex Barrier biomembrane.

Next we inserted the two Bone Trust Plus implants, which achieve excellent primary stability due to their specific macro-design, especially in the presence of intermediate bone quality or quantity. We removed the insertion posts using the hexagonal screwdriver, and inserted the locking screws (Figs. 10 to 12). Lateral coverage of the augmentation followed using

Flex Barrier Hyaluronic Acid Gel (Fig. 13). Flex Barrier is made up of simple and cross-linked hyaluronic acids and was developed especially for guided bone regeneration (GBR). Because of its high viscosity, this material is readily applicable and has high positional stability. After complete coverage of the augmentation, the wound was closed in a tension-free manner.

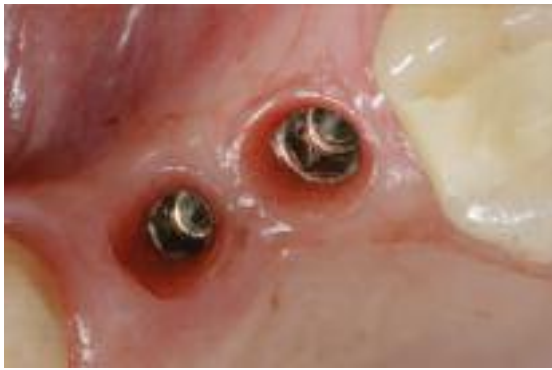

Fig. 14 The exposed Bone Trust Plus implants.

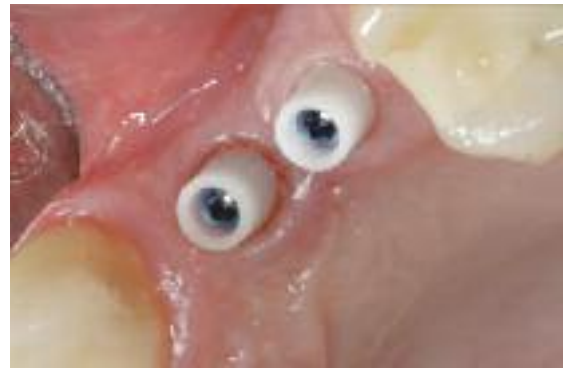

Fig. 15 Situation prior to cementing the crowns.

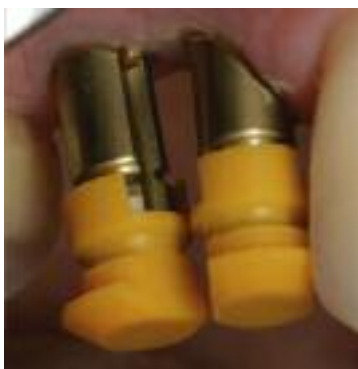

Fig. 16 Repositioning pressure posts.

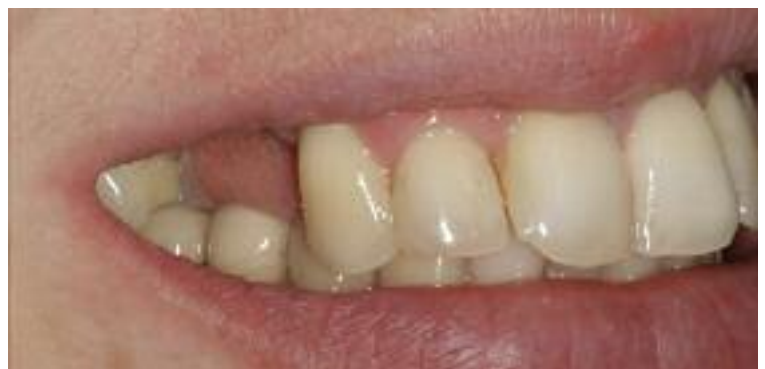

Fig. 17 Lip profile of the patient prior to insertion of the implant-supported superstructure.

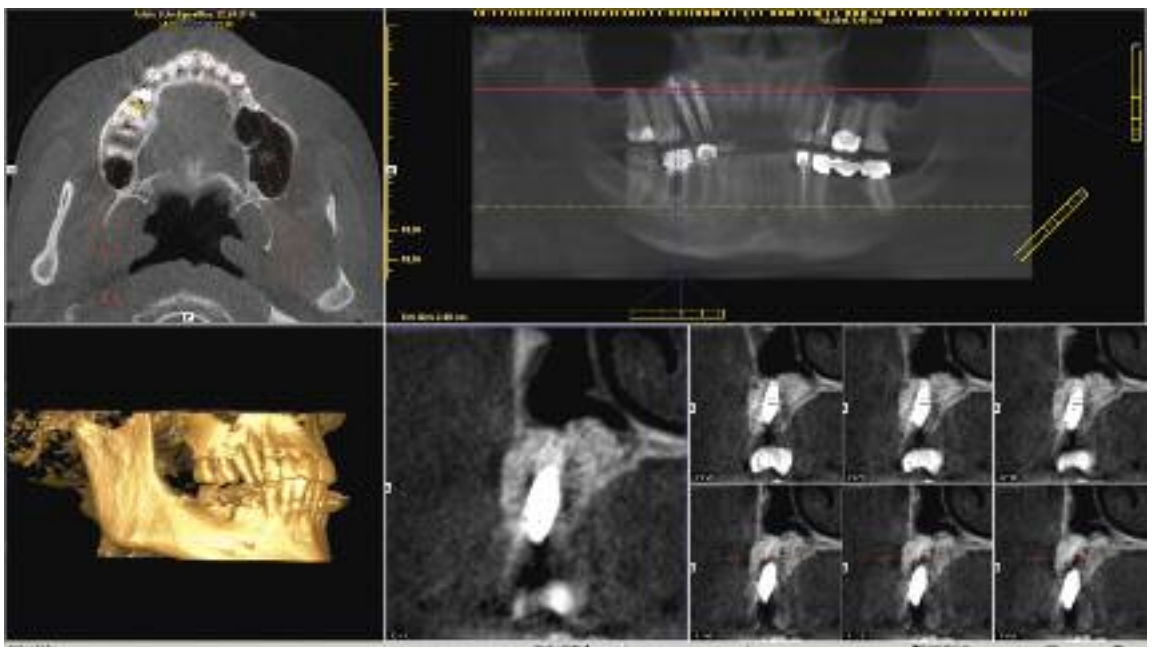


Fig. 18 The CBCT image shows very good ossification of the augmentation material after four months.

Four months after implant insertion, surgery to expose the two Bone Trust Plus implants was performed under local anaesthesia. Our examination showed inflammation-free clinical conditions (Fig. 14). Two gingiva formers were inserted to shape the peri-implant structures (Fig. 15). Ten days later, closed

impressions were obtained using a repositioning technique (Fig. 16). To confirm the success of the augmentation in the area of the maxillary sinus and to verify that permanent osseointegration of the implants could be anticipated, we obtained a three-dimensional X-ray image using the Gendex CB 500 (Kavo) (Fig. 18). The

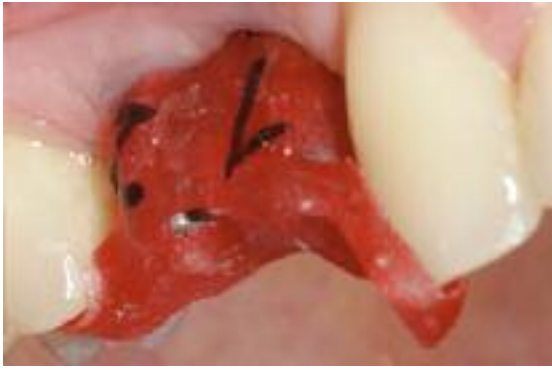

Fig. 19 Pattern resin index to test the correct placement of the abutments.

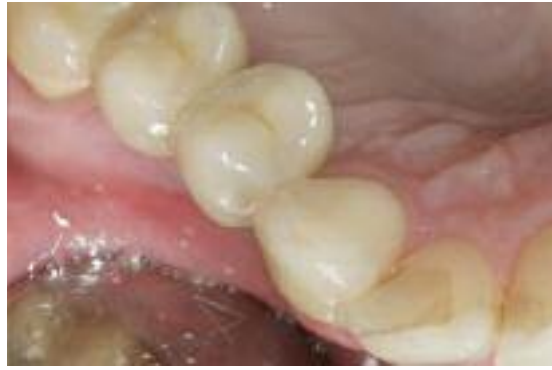

Fig. 20 All-ceramic crowns after cementing.

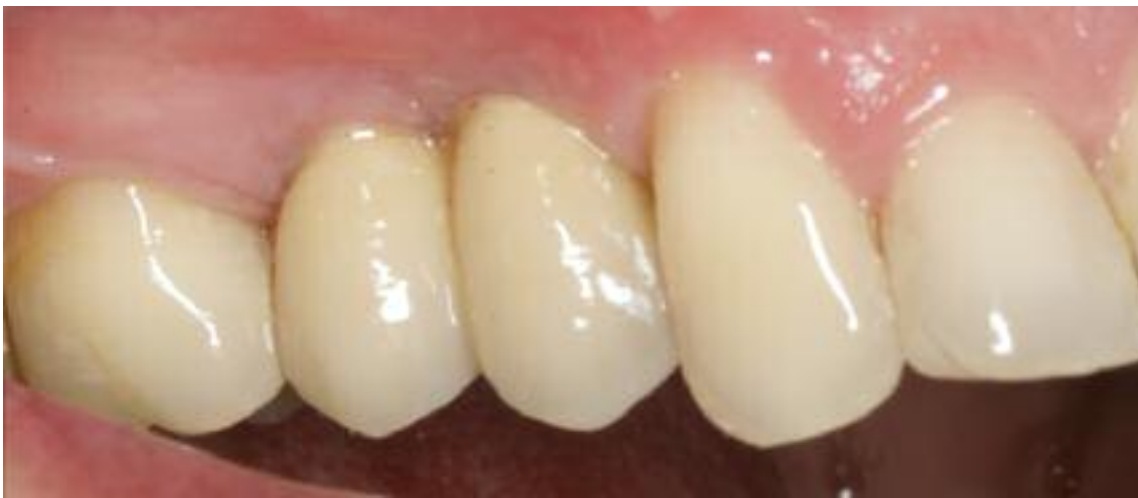

Fig. 21 Prosthetic placement of Bone Trust Plus implants at sites 14 and 15.

X-ray images showed very good ossification of the augmentate, and the two repositioning pressure posts were properly in place without any gaps.

The Bone Trust Plus implant system by Medical Instinct is impressive for the great precision of its components, enabling precise repositioning of the impression copings. After constructing a model, the two all-ceramic abutments were individually prepared, and an all-ceramic superstructure in the form of two premolars was prepared in the dental laboratory.

After completion of the crowns, both abutments were inserted using a pattern resin key and the two retaining screws were attached with 25 Ncm of torque (Fig. 19). The all-ceramic crowns were cemented with ImplaTemp cement, and the treat-

ment session concluded with occlusion and articulation checks (Figs. 20 and 21).

Discussion

We know from the literature that positive effects have been ascribed to hyaluronic acid with respect to wound and bone healing. In implantology, hyaluronic acid represents an ideal carrier material for bone regeneration materials, because hyaluronic acid significantly improves their application. Moreover, it augments the formation rate of new osteoblasts.

Thanks to its viscosity, Flex Barrier contributes to the optimal shielding of the surgical site and thereby helps prevent bacterial contamination of the surgical field. Particularly interesting in general clinical terms are the very good handling properties of the material, its resorbability and good biocompatibility.

Based upon the author's extensive clinical experience with hyaluronic acid, he regards it as a highly promising material for improving therapeutic outcomes in patients. ■

Contact address

Dr Michael Claar
Leipziger Str. 164 · 34123 Kassel · Germany
info@dr-claar.de · www.dr-claar.de